

“COVID arm” detected by MR neurography

ARTICLE INFO

Keywords

COVID-19
Lymphadenopathy
Vaccination

Dear Editor,

Here we present the first report of magnetic resonance neurography (MR neurography) clearly detecting “COVID arm” with lymphadenopathy by Moderna COVID-19 vaccine.

A 68-year-old Japanese female suffering from chronic inflammatory demyelinating polyneuropathy had received the first dose of Moderna COVID-19 vaccine in her left shoulder. On the next day of vaccination, she noticed left shoulder pain and swelling (so called “COVID arm”), but she has been free of other post-COVID-19 vaccination symptoms including Parsonage-Turner Syndrome. On that day, she underwent a MR neurography for regular follow-up evaluation of her

polyneuropathy. Surprisingly, MR neurography revealed marked swelling of the left deltoid muscle and the left axillary lymph nodes at the injected side (Fig. 1). Although recent reports demonstrated axillary lymph nodal activation on ^{18}F -fluorodeoxyglucose positron emission tomography/computed tomography after COVID-19 vaccination [1–3], this is the first report of MR neurography detecting “COVID arm”.

Ethics statement

Written informed consent was obtained from the patient for the publication of this case report in accordance with the Declaration of Helsinki.

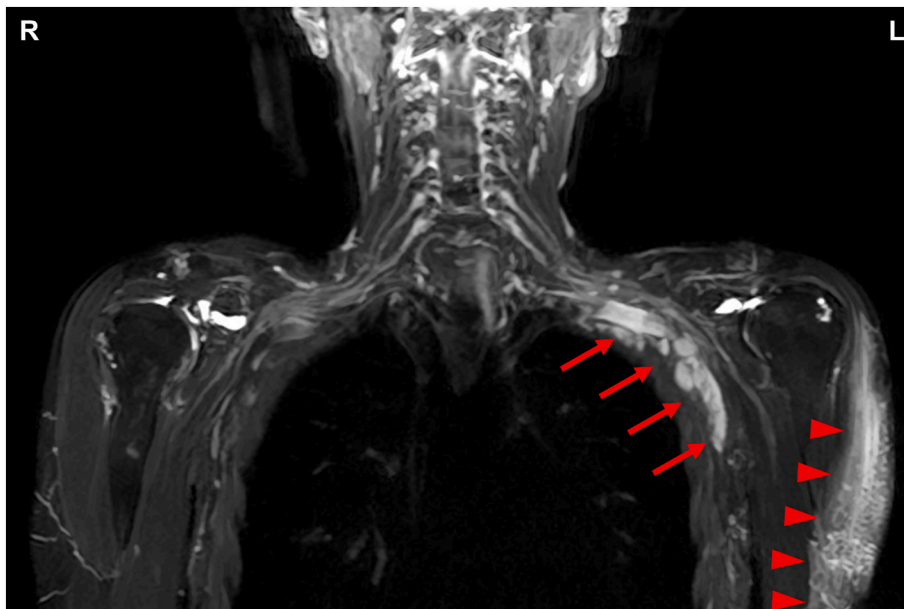


Fig. 1. MR neurography of the cervical nerve roots the next day of Moderna COVID-19 vaccination in the left shoulder detected severe swelling of the left deltoid muscle (arrow heads) and the left axillary lymph nodes (arrows).

<https://doi.org/10.1016/j.ensci.2021.100377>

Received 8 September 2021; Accepted 31 October 2021

Available online 3 November 2021

2405-6502/© 2021 The Authors.

Published by Elsevier B.V. This is an open access article under the CC BY-NC-ND license

(<http://creativecommons.org/licenses/by-nc-nd/4.0/>).

Study funding

The authors report no targeted funding.

Declaration of Competing Interest

The authors report no disclosures relevant to the manuscript.

References

- [1] M. Eifer, Y. Eshet, Imaging of COVID-19 vaccination at FDG PET/CT, *Radiology* 299 (2021), E248.
- [2] D.G. Schroeder, S. Jang, D.R. Johnson, et al., Frequency and Characteristics of Nodal and Deltoid FDG and ¹¹C-Choline Uptake on PET Performed After COVID-19 Vaccination, *AJR Am. J. Roentgenol.* 217 (5) (2021) 1206–1216.
- [3] M. Orevi, A. Chicheportiche, S. Ben-Haim, Lessons learned from post-COVID-19 vaccination PET/CT studies, *J. Nucl. Med.* (2021), <https://doi.org/10.2967/jnumed.121.262348>.

Hiroyasu Komiya, Kohei Harada, Ryoji Morishita, Shunta Hashiguchi, Mikiko Tada, Kenichi Tanaka, Hiroshi Doi, Hideyuki Takeuchi^{*}, Fumiaki Tanaka^{*}
Department of Neurology and Stroke Medicine, Yokohama City University Graduate School of Medicine, 3-9 Fukuura, Kanazawa-ku, Yokohama 236-0004, Japan

^{*} Corresponding authors.

E-mail addresses: htake@yokohama-cu.ac.jp (H. Takeuchi),
ftanaka@yokohama-cu.ac.jp (F. Tanaka).