



Since January 2020 Elsevier has created a COVID-19 resource centre with free information in English and Mandarin on the novel coronavirus COVID-19. The COVID-19 resource centre is hosted on Elsevier Connect, the company's public news and information website.

Elsevier hereby grants permission to make all its COVID-19-related research that is available on the COVID-19 resource centre - including this research content - immediately available in PubMed Central and other publicly funded repositories, such as the WHO COVID database with rights for unrestricted research re-use and analyses in any form or by any means with acknowledgement of the original source. These permissions are granted for free by Elsevier for as long as the COVID-19 resource centre remains active.

COVID-19 Scientific Communication

COVID-19 Vaccine-Induced Radiation Recall Phenomenon

Viacheslav Soyfer, MD,* Orit Gutfeld, MD,* Sivan Shamai, MD,[†]
Albert Schlocker, MS,* and Ofer Merimsky, MD[†]



*Department of Radiation Oncology and [†]Unit of Soft Tissue and Bone Oncology, Division of Oncology, Tel-Aviv Medical Center, affiliated with Sackler School of Medicine, Tel-Aviv University

Received Feb 11, 2021, and in revised form Feb 22, 2021. Accepted for publication Feb 23, 2021.

Radiation recall phenomenon (RRP) is an uncommon, late occurring, acute inflammatory skin reaction that emerges in localized areas coincident with previously irradiated radiation therapy (RT) treatment fields. RRP has been known to be triggered by a number of chemotherapy agents. To the best of our knowledge, this report is the first description of RRP after administration of the Pfizer-BioNTech vaccine for COVID-19, or any other currently available vaccine against COVID-19. Acute skin reactions were observed in 2 RT patients with differing timelines of RT and vaccinations. In both cases however, the RRP presented within days of the patient receiving the second dose of vaccine. For each RT course, the treatment planning dosimetry of the radiation fields was compared with the area of the observable RRP. RRP developed within the borders of treatment fields where prescription dose constraints were prioritized over skin sparing. Our observation is currently limited to 2 patients. The actual incidence of RRP in conjunction with Pfizer-BioNTech vaccine or any other vaccine against COVID-19 is unknown. For patients with cancer being treated with radiation with significant dose to skin, consideration should be given to the probability of RRP side effects from vaccinations against COVID-19. © 2021 Elsevier Inc. All rights reserved.

Introduction

Radiation recall phenomenon (RRP) is a late effect, acute skin reaction associated with therapeutic irradiation, triggered by something other than radiation. It usually appears more than 1 week after the completion of radiation therapy (RT) and is typically localized to the RT field entry points. The RRP is frequently wrongly misinterpreted as radiosensitization if the skin reaction appears within 7 days after radiation treatment.¹

Radiation recall syndrome was first described by D'Angio et al in 1959.² Though oncologists are generally aware of RRP, little is known about its pathophysiology. Burris and Hurtig³ summarized hypotheses regarding RRP.

The increased sensitivity of the stem cells in the field of radiation may result in an acute reaction to subsequent chemotherapy and idiosyncratic drug hypersensitivity reactions.¹ The level of inflammation-mediating cytokines induced by radiation may be upregulated by chemotherapeutic agents.⁴

Although the development of RRP is usually associated with cytotoxic drugs, several noncancer treatments can evoke this syndrome.⁵⁻⁹ Although RRP mostly presents in a mild form, in just under 10% of cases symptoms can be severe and include moist desquamation in areas other than skin folds, and bleeding can be induced by minor trauma or abrasion.¹ The decision to use systemic cancer treatments in conjunction with RT is frequently limited by the risk of

Corresponding author: Viacheslav Soyfer, MD; E-mail: slavas2506@gmail.com

Disclosures: none.

Data sharing statement: Research data are stored in an institutional repository and will be shared upon request to the corresponding author.

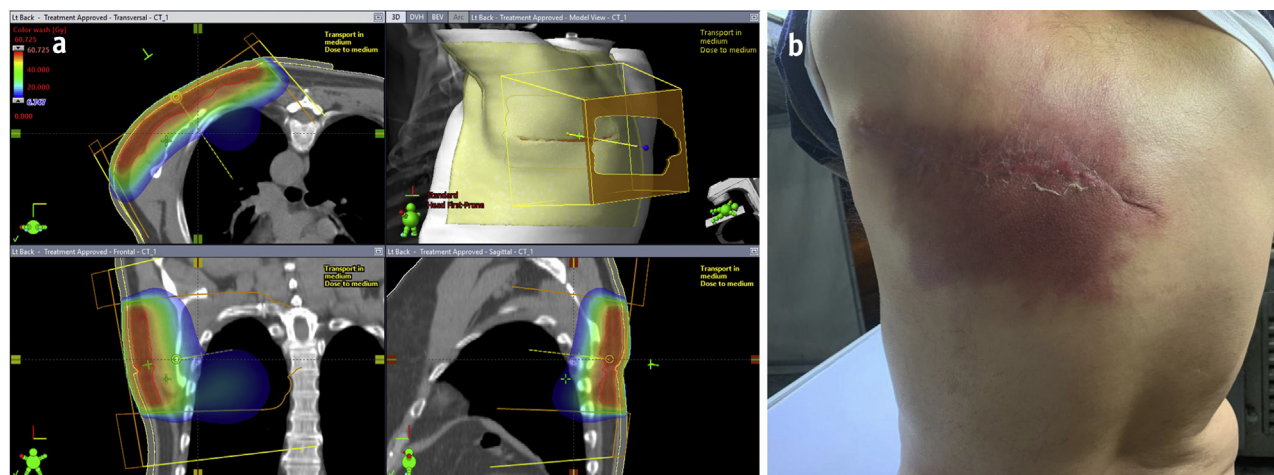


Fig. 1. (a) Posterior chest wall treatment plan (Patient 1). (b) Acute skin reaction after COVID-19 vaccination (Patient 1).

developing devastating skin reactions. To decrease the risk of severe RRP, a greater time interval between RT and the start of chemotherapy is usually recommended.¹⁰

The regulations imposed for the COVID-19 pandemic are challenging for a wide community of patients with cancer, often requiring isolation and restricted visitation. Clinical oncologists who deal with the administration of multiple systemic treatments and RT must now factor COVID-19 vaccination into their treatment paradigms. The official website of the American Society of Clinical Oncology states that "At this time, patients undergoing treatment may be offered vaccination against COVID-19 as long as any components of the vaccine are not contraindicated. Strategies such as providing the vaccine in between cycles of therapy and after appropriate waiting periods can be used to reduce the risks while maintaining the efficacy of vaccination."¹¹ The evolving dramatic changes in view of COVID-19 are beyond the discussion of this report. The RRP we observed associated with the Pfizer-BioNTech vaccine was reported to the management

of the Tel Aviv Medical Center following a process regulated by the Israel Ministry of Health.

Methods and Materials

In our RT department, we observed 2 patients who developed acute skin reactions in previously irradiated areas after receiving 2 doses of Pfizer-BioNTech vaccine. The reactions were diagnosed as RRP.

Case presentation—patient no. 1

A 68-year-old otherwise healthy male had a metastatic soft tissue sarcoma (unclassified spindle cell sarcoma) involving the soft tissues of the posterior chest wall and 1 lesion in the right lung. Preoperative radiation therapy of 50 Gy in 25 fractions with electrons (mixed 9 and 12 MeV) prescribed to the 90% isodose level with a 0.5 cm bolus over the entire field was delivered to his back (Fig. 1a).

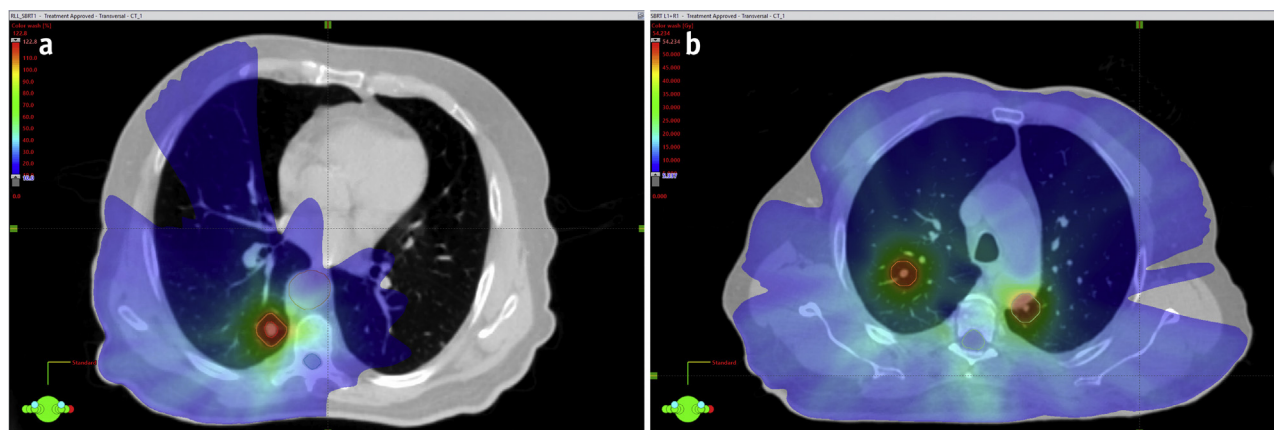


Fig. 2. Stereotactic body radiation therapy (SBRT) dose distributions for lung treatments (Patient 1).

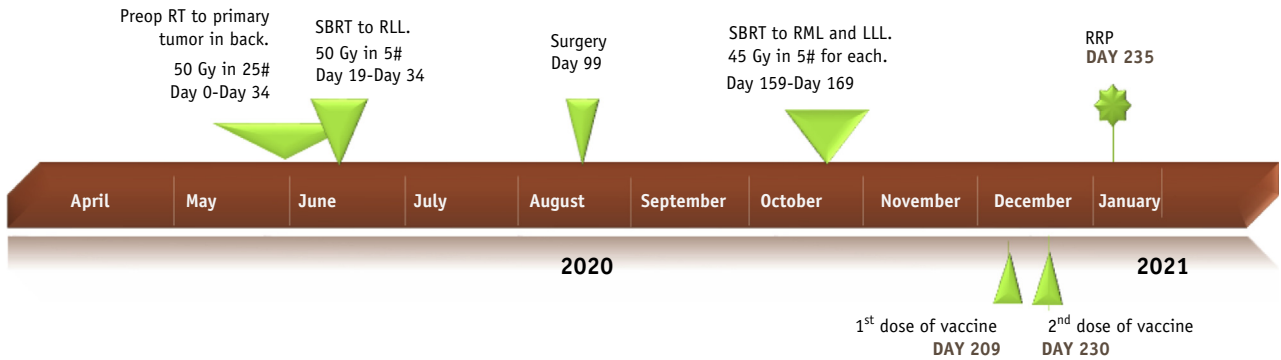


Fig. 3. Timeline for Patient 1.

Over the last 2 weeks of the electron course, the patient received stereotactic body radiation therapy, 50 Gy in 5 fractions to a lesion in the right lower lobe. Two months after the RT, the patient underwent a complete resection of the residual disease in the posterior chest wall. This was followed by an additional course of stereotactic body radiation therapy to 2 other lesions, 45 Gy in 5 fractions (Fig. 2). The patient did not receive any systemic chemotherapy during the observed period, nor any therapeutic drugs known to cause RRP.

Six months after the initial RT to the posterior chest wall, the patient received his first COVID-19 vaccination, followed by a second shot 21 days later. This sequence of RT and vaccinations is detailed in the timeline (Fig. 3).

Five days after the second shot of the vaccine, an acute skin reaction developed, associated with pain, burning sensation, redness, and mild skin exfoliation in the area of the posterior chest wall electron field (Fig. 1b). It can be seen that the electron port shape closely resembles the erythematous area. The RRP was treated symptomatically with topical steroids and painkillers. The reaction resolved within a few days. No pulmonary symptoms were reported, and no RRP developed in areas other than described.

Case presentation—patient no. 2

A 64-year-old otherwise healthy male with metastatic soft tissue sarcoma (solitary fibrous tumor) received radiation to 2 treatment sites: lumbar vertebrae after surgery for spinal cord compression and subsequent palliative RT to a painful metastatic lesion in the right chest wall. The lumbar spine was treated by 2 posterior oblique 6 MV photon fields (Fig. 4), which provided partial skin sparing. The chest wall tumor was treated with 2 tangential 6 MV photon fields with 0.5 cm bolus covering the treatment area, resulting in coverage of the target with high but tolerable skin dose (Fig. 5a).

The first shot of vaccine was administered 5 days before the conclusion of the RT. The second dose of vaccine followed 21 days later, approximately 2 weeks after cessation of RT. This sequence is detailed in the timeline (Fig. 6).

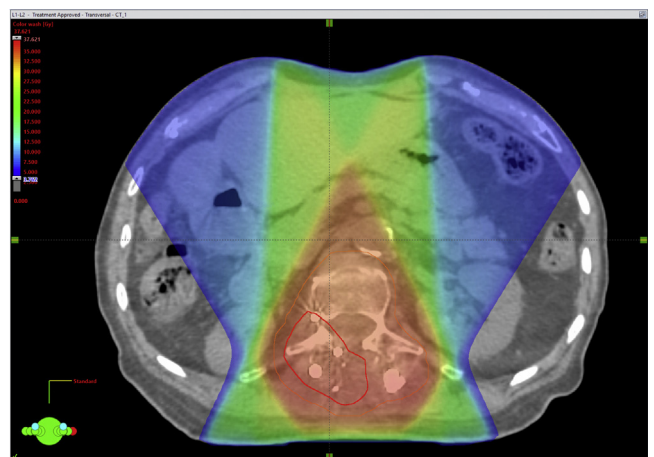


Fig. 4. Lumbar spine treatment plan—oblique fields (Patient 2).

Six days after the second vaccination, an acute skin reaction was noted, manifested by skin redness and itching sensation. No local therapy or painkillers were needed. The reaction faded slowly within the following week (Fig. 5b).

RRP was not observed on the skin covering the lumbar spine.

Discussion

One of the promising ways to overcome the COVID-19 pandemic is through recently developed vaccines. For some RT patients, receiving the highly effective vaccination will supersede any low-risk RRP side effects that may occur from concurrent or prior RT. To the best of our knowledge, our clinical observations are the first RRP reported after administration of the Pfizer-BioNTech vaccine for COVID-19. The real incidence of this phenomenon is unknown. We cannot make any conclusions or predictions on the time needed between RT and administration of the COVID-19 vaccine to avoid RRP. Notably, in 1 of our patients the RRP erythema appeared 6 months after the radiation exposure, whereas the other occurrence was only shortly after the

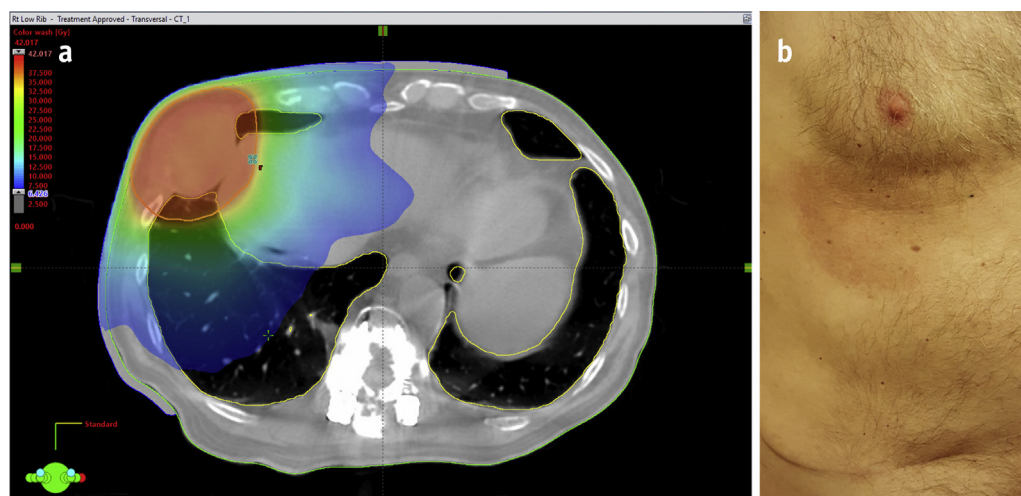


Fig. 5. (a) Anterior chest wall treatment plan (Patient 2). (b) Acute skin reaction after COVID-19 vaccination (Patient 2).

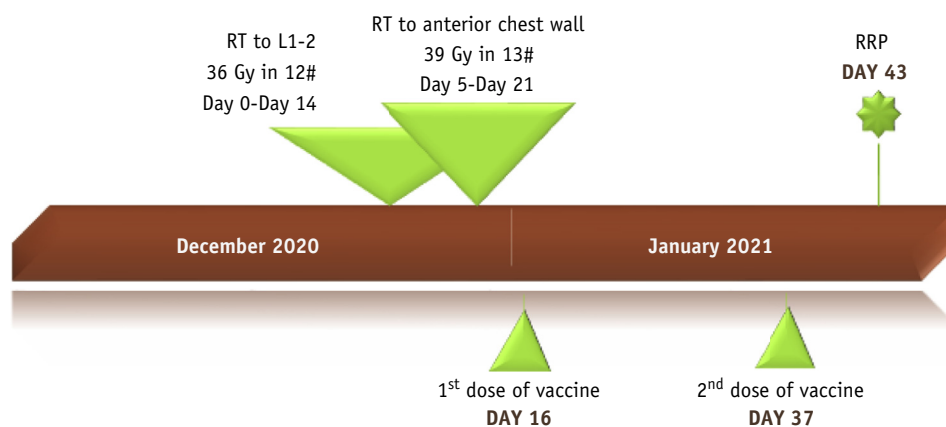


Fig. 6. Timeline for Patient 2.

cessation of RT. Similarly, the determination of a radiation dose threshold for RRP cannot be estimated from this small observation.

Conclusions

For patients with cancer, recommendations regarding vaccination are evolving. We observed in our clinic the development of RRP in 2 patients with varying courses of RT, seemingly triggered by the COVID-19 vaccine. Reasonable considerations should be applied to decisions regarding vaccination of on-treatment RT patients. Patients and physicians should be aware of the potential for the RRP side effect after COVID-19 vaccination.

References

1. Camidge R, Price A. Characterizing the phenomenon of radiation recall dermatitis. *Radiother Oncol* 2001;59:237-245.
2. D'Angio GJ, Farber S, Maddock CI. Potentiation of x-ray effects by actinomycin. *Radiology* 1959;73:175-177.
3. Burris HA, Hurtig J. Radiation recall with anticancer agents. *Oncologist* 2010;15:1227-1237.
4. Azria D, Magne N, Zouhair A, et al. Radiation recall: A well-recognized but neglected phenomenon. *Cancer Treat Rev* 2005;31:555-570.
5. Garza LA, Yoo EK, Junkins-Hopkins JM, et al. Photo recall effect in association with cefazolin. *Cutis* 2004;73:79-80.85.
6. Jolivet J, Landry L, Pinarf MF, et al. A phase I study of trimetrexate, an analog of methotrexate, administered monthly in the form of nine consecutive daily bolus injections. *Cancer Chemother Pharmacol* 1987;20:169-172.

7. Weiss RB, James WD, Major WB, et al. Skin reactions induced by trimetrexate, an analog of methotrexate. *Invest New Drugs* 1986;4:159-163.
8. Cho S, Breedlove JJ, Gunning ST. Radiation recall reaction induced by levofloxacin. *J Drugs Dermatol* 2008;7:64-67.
9. Abadir R, Liebmann J. Radiation reaction recall following simvastatin therapy: A new observation. *Clin Oncol (R Coll Radiol)* 1995;7:325-326.
10. Yeo W, Johnson PJ. Radiation-recall skin disorders associated with the use of antineoplastic drugs. Pathogenesis, prevalence, and management. *Am J Clin Dermatol* 2000;1:113-116.
11. American Society of Clinical Oncology. Available at: <https://www.asco.org/asco-coronavirus-resources/covid-19-patient-care-information/covid-19-vaccine-patients-cancer>. Accessed February 11, 2021.